



# Histomorphometry of Explanted Dental Implants

J. Lemons, M. Anabtawi, P. Beck, and V. Morgan  
 Department of Prosthodontics, School of Dentistry, University of Alabama at Birmingham



## ABSTRACT

**Objective:** The significant success (%) and longevities of root form dental implants affords opportunities to evaluate and classify device-to-bone interfaces. These opportunities are based on a small percentage that come to revision. Histomorphometric analyses of human explants permits multiple comparisons including in vitro and laboratory in vivo study outcomes.

**Methods:** A clinical group (headed by VM) have removed root form implants, where indicated clinically, by Magnitudes of osseous integration from three time periods (about 2, 5 and 10 years) are shown in Figure 2 (A-C) trephine osteotomy. The implant body and bone remain in bloc and specimens were immediately fixed in 10% buffered formalin and transferred with selected records for analysis. Specimens were: macrophotographed, evaluated stereomicroscopically; oriented, embedded; prepared by Exakt® sectioning; stained; and evaluated along longitudinal mid-line thin (20-50 micrometer) sections by Bioquant® imaging for bone quality, quantity, and specific anatomical characteristics.

**Results:** Eighty\* plateau-type design received from one source over the past 3 years. Specimens evaluated by staff and students resulted in: (1) adequate bone for 41 longitudinal section histomorphometric analyses; (2) percent bone integration from 5 to 95% that was not significantly correlated ( $p > 0.05$ ) with in vivo factors other than anatomical location; and (3) interfacial bone structures of a mature and osteonal-type anatomy reported previously<sup>1</sup>. These results support that dental implant-to-bone interfaces can be stable over time and function with bone remodeling leading to a functional anatomy that is characteristic of the implant design. Comparative analyses with screw-type designs of the same biomaterial are scheduled.

**Conclusions:** (1) en bloc explants from in vivo functional periods from 3 to 126 months showed osseointegration percentages from 5 to 95%; and (2) the bone anatomy was a mature osteonal type structure, characteristic of plateau type implant designs.  
 \*Partial student support from Bicon Inc, Boston, MA is acknowledged.  
 Lemons, J, J Oral Imp, 2004 and in Davies, J. Ed., *Bone Engineering*, 2000.

## INTRODUCTION

**Rationale:** Primary reasons for conducting detailed in vitro analyses of explanted surgical implants, tissues and records are to evaluate (1) why the implant/restoration was lost; (2) the conditions of the device at removal to assure stability of the overall structure and properties of the construct; (3) detailed histomorphometry of the tissue-to-implant interfacial region to assess relative biocompatibility; and (4) recommendations to further improve clinical outcomes.

**Objective:** The central objective of this particular study was to provide quantitative assessments of the bone-to-implant interfacial zone (osseous integration) and the local anatomical conditions of the bone over time and function. Where possible, these data were correlated with clinical parameters leading to a goal of continuously improving dental implant based clinical care. (IADR Poster #1040, Muna Anabtawi)

## Materials and Methods

**Identifying, Explanting, Packaging, Transferring, Receiving and Recording**  
 The “ailing and failing” implant sites were identified by the clinical team leader (VM) through radiographic and clinical intraoral examinations. These type implant constructs were mostly individual free standing (crown/abutment/implant) and the clinician and patient decide about removal from overall clinical-functional criteria.

If explanted, implants within bone were removed en bloc using an irrigated surgical trephine sized to the implant diameter and length. After explanation, the implant construct and associated tissues were immediately placed in 10 percent buffered formalin, and with approvals, transferred where confidential records were maintained. Overall constructs were provided a code number lxxx, examined stereomicroscopically and macrophotographed to establish the status and the radial orientation for any longitudinal sectioning. The specimens were imbedded and processed with an Exakt® system leading to longitudinal mid-line thin sections of 20-50 micrometer thicknesses.

### Examining and Histomorphometry

Nondecalfified thin sections were examined in transmitted and reflected light with bone regions evaluated quantitatively for bone growth rates or processed using Sanderson’s Red Bone Stain for area and interface measurement. The implant surface-to-bone regions were subdivided into longitudinal parts of 0.5 millimeter thickness to compare the contact interface, the bone between the implant plateaus and the bone away from the implant body. A Bioquant Image Analysis System® provided bone areas and linear mineralized bone to implant contact (osseous integration). Bone anatomy and quality of the bone was also evaluated with data collected without knowledge of the specific clinical history.

## RESULTS

The sequence of processing is depicted in Figure 1 (A-C) showing as received (1A), a macro view of the section (1B) and a higher magnification image of the bone-to-implant interface (1C).


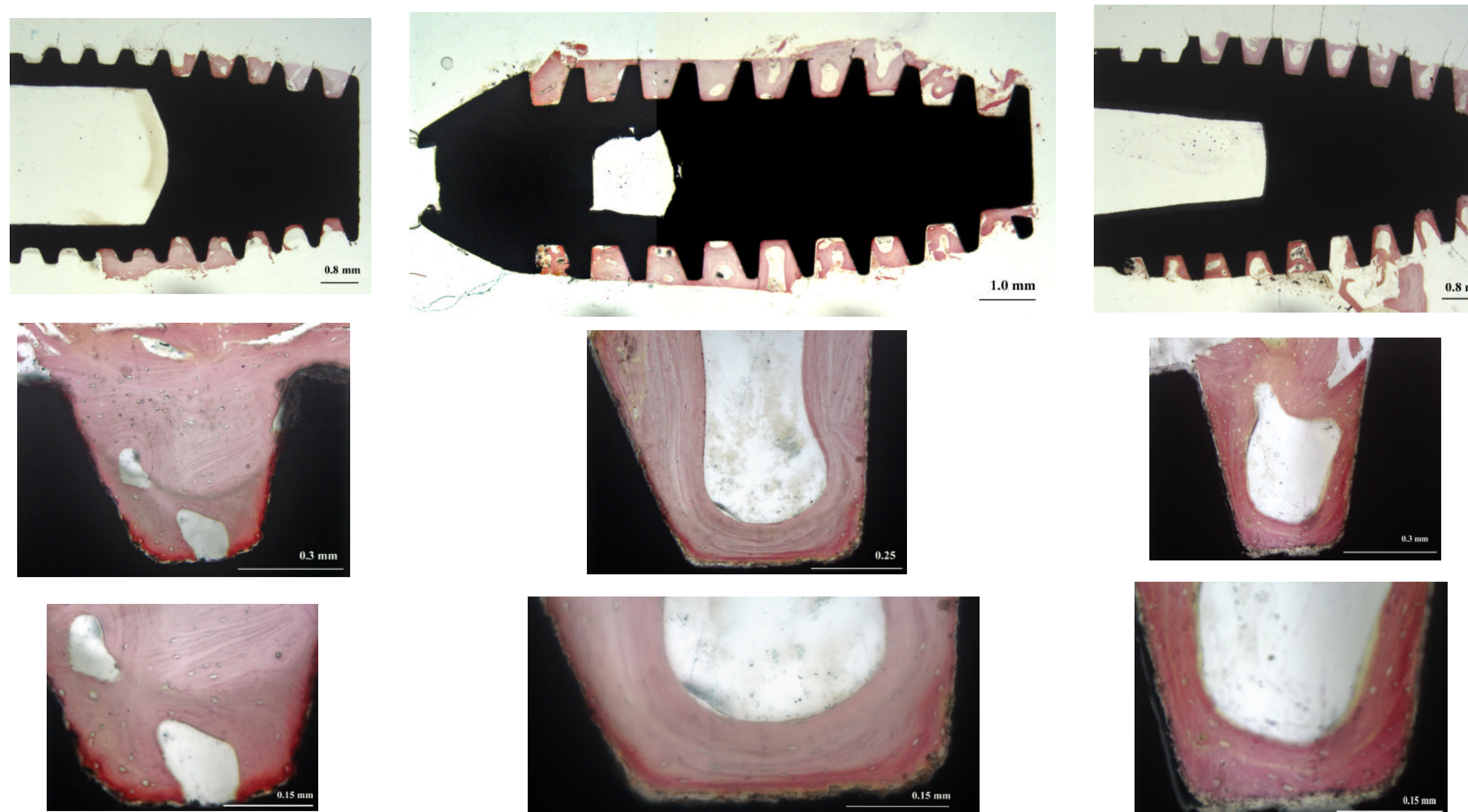


Figure 1 (A-C). Implant processing for analysis

Magnitudes of osseous integration from three time periods (18, 48 and 120 months) are shown in Figure 2 (A-C).



A. 18 months in vivo: 51% bone integration

B. 48 months in vivo: 65% bone integration

C. 120 months in vivo: 72% bone integration

Figure 2 (A-C). Histomorphometric images of osseous integration.

The magnitudes of osseous integration varied from 5 to 95 percent. The anatomical characteristics of the bone location within the plateau regions were most interesting, in that most demonstrated significant vascularity and a sequential semi-circular structure between the plateaus that is characteristic of osteonal-like bone. The relative importance of this anatomy is under on-going investigation.

Within this overall explant series, collected over three years, a total 80 devices were transferred with 41 of these having adequate bone to justify histomorphometry. The overall grouping of the specimens where times were known are expressed in terms of percentage osteointegration versus time in vivo in Figure 3.

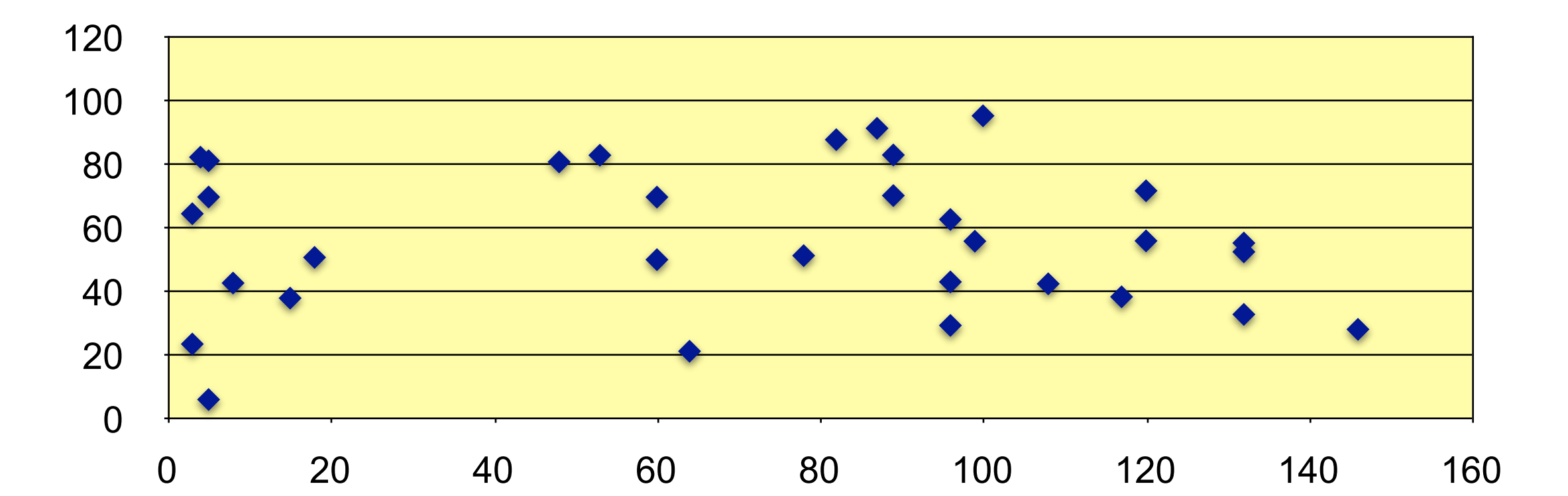


Figure 3. Osseous Integration Percentage vs. time in vivo for 41 implants.

## CONCLUSIONS

The 41 explanted constructs where bone was adequate for histomorphometrical analyses along mid-line non-decalcified sections led to the following conclusions. Histomorphometric analyses of 41/80 explanted dental implant devices of plateau body section design from in vivo periods to more than 10 years showed osseous integration from 5-95 percent. The various osseous integrated devices showed a bone anatomy between the plateaus’ that was a mature osteonal-like structure. On-going studies will consider more detailed characterizations of the bone regions and possible correlations with clinical factors.

## REFERENCES

- Lemons, J.E.: Bone-to-Biomaterial Interfaces of Retrieved Implants, In: *The Bone-Biomaterial Interface*, (Davies, J.E., Ed.) University of Toronto Press, (Chapter 38) 419-424, 1991.
- Lemons, J. Biomaterials, Biomechanics, Tissue Healing, and Immediate-Function Dental Implants. *J of Oral Implantology*, Vol. XXX/No. Five, 2004m pg 318-324.
- Lemons, J. World Symposium, 20th Anniversary, Bicon Dental Implants, Boston, MA, Sept. 8-10, 2005.
- Anabtawi, M, Beck, P., Bartolucci, A., Lemons, J., Histological Analysis for Forty-One Retrieved Dental Implants, IADR, New Orleans, LA, March, 2007.

## ACKNOWLEDGEMENTS

Partial funding from Bicon LLC, the University of Alabama at Birmingham and NIDCR grant T32-DE14300 is acknowledged. No royalties, consulting fees or honoraria were received by any of the UAB investigators.