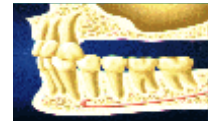



Sinus Augmentation Procedure Using Beta-Tricalcium-Phosphate: Histological Analysis of Grafted Bone at Time of Implant Placement



Ulrike Schulze-Späte¹, Thomas Dietrich^{1,2}, Justine Dobeck³, Rayyan Kayal¹, Adrian Time¹, Ziedonis Skobe³, Serge Dibart¹

¹Department of Periodontology and Oral Biology, Goldman School of Dental Medicine, Boston University, Boston, MA,

²University of Birmingham, UK, ³The Forsyth Institute, Boston, MA

ABSTRACT

Background: Implant placement in the edentulous maxilla often represents a clinical challenge due to insufficient bone height after crestal bone resorption. Several graft materials have been evaluated for augmenting the maxillary sinus in order to compensate for the lost vertical dimension. Allografts are readily available, there is no risk of disease transmission and they do not require a second site surgery. The aim of this study was to evaluate the development and maturation of augmented bone in the maxillary sinus using beta-tricalcium-phosphate.

Methods: Patients (n=10, female: 4/male 6, age 30-64) with the need for rehabilitation of their dentition in the posterior maxilla and no present medical contraindications were included in the study. Beta-tricalcium-phosphate (Synthograft, Bicon, Boston, MA) mixed with the patient's blood was implanted into the sinus cavity, which was accessed using a lateral window technique. 6-8 month post sinus elevation, bone biopsies were taken and implants were placed simultaneously. All specimens were demineralized and subjected to staining procedures (H&E, Goldner's staining, TRAP). Slides were analyzed using light microscopy for total surface area, the surface area that consisted of bone and the surface area that consisted of graft material (all in mm² and expressed as % of the total surface.). Osteoclasts were identified and counted as number per mm².

Results: All implants were placed achieving primary stability and restored 4 months after placement. H&E and Goldner's stainings demonstrated the presence of vital woven bone in the grafted area with only a few remaining graft particles (total bone surface: 31.3%±15.8% at 6 month and 36.4%±5.4% at 8 month, total graft surface: 13.9%± 4.7% at 6 month and 9.6%±4.8%). In addition, TRAP staining revealed presence of osteoclasts surrounding those particles (osteoclast number: 1.23±0.25 per mm² at 6 month and 1.4±0.4 per mm² at 8 month). A lack of inflammatory reaction was noticed with the use of this graft material. During 12 month follow up, no implant failure or complications were observed.

Conclusion: Beta-tricalcium-phosphate has the advantage of exhibiting no risks of disease transmission and can be available in unlimited quantities. It is clinically easy to use, having great handling properties and appears to cause no persistent inflammatory reaction in surrounding bone. Overall this material seems to provide adequate stability at time of implant placement.

Therefore, augmentation of the maxillary sinus with beta-tricalcium-phosphate represents a viable option for increasing vertical bone height in the posterior maxilla prior implant placement.

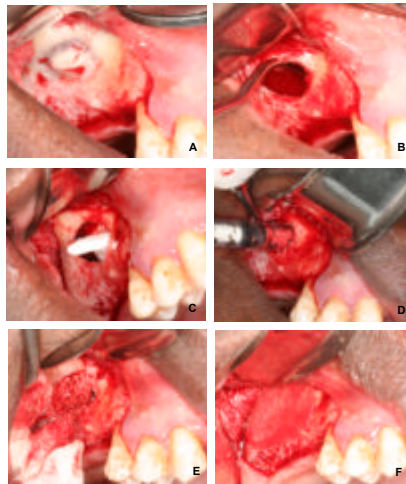
METHODS

Implantation. Patients (n=10, female: 4/male 6, age 30-64) with the need for rehabilitation of their dentition in the posterior maxilla and no present medical contraindications were included in the study. Beta-tricalcium-phosphate (Synthograft, Bicon, Boston, MA) mixed with the patient's blood was implanted into the sinus cavity, which was accessed using a lateral window technique. 6-8 month post sinus elevation, bone biopsies were taken and implants were placed simultaneously.

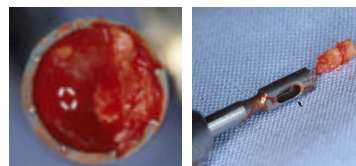
Implant Surgery. Core biopsies of the grafted area were taken at the time of implant placement and further analyzed using H&E staining, Goldner's staining, TRAP staining according to standard protocols. Slides were analyzed using light microscopy for total surface area, the surface area that consisted of bone and the surface area that consisted of graft material (all in mm² and expressed as % of the total surface.). Osteoclasts were identified and counted as number per mm².

CLINICAL PROCEDURE

Sinus Augmentation Procedure



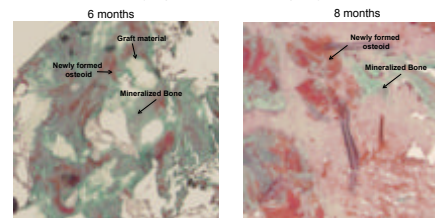
Core Retrieval at Time of Implant Placement



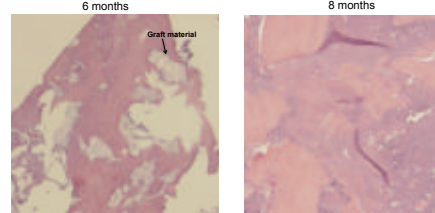
RESULTS

Histological Analysis

Goldner's Staining
(Representative Examples)



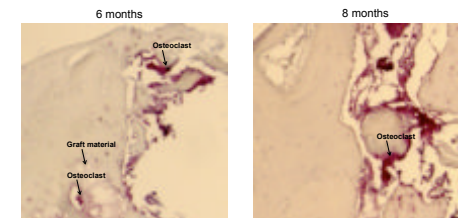
H&E staining
(Representative Examples)



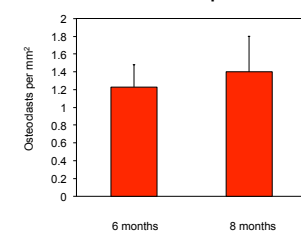
RESULTS

Histological Analysis

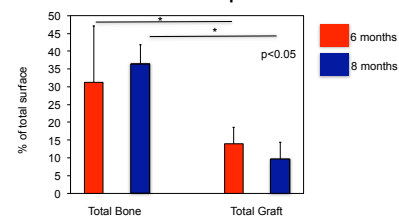
TRAP Staining
(Representative Examples)



Osteoclasts per mm² in Core Biopsies



Analysis of Bone and Graft Material in Core Biopsies



CONCLUSIONS

- Total bone increases over time, whereas, the amount of graft material diminishes during healing and remodeling. Amount of bone formation is comparable to results that can be achieved with other grafting materials (such as DFDBA) as shown in previous studies. Overall, beta-tricalcium-phosphate appears to cause no persistent inflammatory reaction in surrounding bone, hence making this grafting compound a tissue friendly material that is well tolerated by the human body.
- Augmentation of the posterior maxilla with beta-tricalcium-phosphate represents a viable option for increasing vertical bone height in the posterior maxilla prior implant placement.